

Induced dedifferentiation: A possible alternative to embryonic stem cell transplants

Robert O. Becker*

Department of Orthopedic Surgery, Upstate Medical Center, State University of New York, Syracuse, NY 13210, USA

Abstract: Induction of local tissue regeneration in the human would best be accomplished if the patient's own cells at the desired site could be caused to dedifferentiate into the required embryonic stem cells. A system involving the electrical iontophoretic introduction of free silver ions into human wounds for their antibiotic effect has been in clinical use since 1975. In addition to a major antibiotic effect, the technique was found to produce the regeneration of all local tissues, apparently by stimulating dedifferentiation of mature human cells. More recently the use of a newly developed silvered nylon fabric has been found to have similar results without the need for electrical parameters. The results of a preliminary laboratory and clinical study of this material are presented.

Keywords: Stem cells, dedifferentiation, silver ion, tissue regeneration

1. Introduction

A major area of present interest in medical research is the use of totipotent, stem cells derived from human embryos as implants in areas of diseased or damaged tissues with the intent to produce local tissue regeneration [14]. This technology has both ethical and technical difficulties of considerable import [19]. In addition, it neglects the present knowledge of the cellular processes involved in regeneration in those animals naturally capable of this process [8].

The signature event in salamander limb regeneration is the appearance of a mass of undifferentiated cells, known as the blastema, at the site of limb amputation. This structure, which could be considered the equivalent of an implant of human fetal stem cells in clinical medicine, subsequently gives rise to the regenerated structure by a growth process similar to embryogenesis. The origin of the blastema has been hotly contested over the past 100 years with one group claiming it was formed by migration of pre-existing, prim-

itive "reserve" cells to the site, and the other claiming that mature cells at the injury site reverted to their embryonic state. Over time the concept that dedifferentiation of mature cells back to their embryonic state was impossible became firmly established as inviolate dogma [18]. While this view was primarily a philosophical concept lacking any basis in scientific fact, it effectively prevented any research on the competing concept of dedifferentiation until the past few decades. It is now accepted that the major source of blastemal cells in the salamander is the reversal of the differentiated state in the mature cells located in the amputation site [16]. These dedifferentiated cells subsequently undergo clonal expansion, reenter the cell cycle and redifferentiate into the required cell types to produce regeneration of the missing structures [8]. At the same time the presence of progenitor or stem cells, akin to the original "reserve" cells, in mature tissues of higher vertebrates become established [13].

Much is now known about dedifferentiation. In amphibians it is apparently the result of the response of mature somatic cells to specific, neurally generated direct current electrical factors at the injury site [2,6]. Simulation of these factors *in vitro* produced the rapid morphological dedifferentiation of mature amphibian ery-

*Address for correspondence: Box 278 HC 62, Lowville, NY 13367, USA. Tel.: +1 315 376 8072.

throcytes [7]. Application of the same electrical factors to limb amputation sites in mature amphibians not normally capable of limb regeneration was found to result in the regrowth of an anatomically complete limb [15]. Mature mammalian cells, including human, do not similarly respond, *in vitro* or *in vivo*, to a range of electrical factors including those associated with amphibian regeneration [1]. However, human children, up to the age of approximately 10 years, have the capability of regenerating traumatically amputated finger tips [10]. This process is associated with the appearance of a blastema-like structure and measurable electrical potentials indistinguishable to those demonstrated by regenerating salamanders [11]. Finally, application of artificially generated electrical currents and voltages duplicating those found in regenerating salamander limbs to forelimb amputations in weanling rats results in organized, multi-tissue, partial limb regeneration [3]. At present, it cannot be determined if these examples of naturally occurring or electrically stimulated mammalian regeneration are the result of proliferation of a small, pre-existing stem cell population or the dedifferentiation of mature mammalian cells.

However, dedifferentiation and clonal expansion of mature, adult human somatic cells was serendipitously observed during experiments designed to produce a local antibiotic effect by iontophoresing free silver ions into infected wounds [4]. The free silver ions were derived from a positive, electrode, consisting of silver coated nylon fabric, applied directly to the wound. This treatment results in the production of a profuse wound exudate containing morphologically undifferentiated cells and a rapid healing response similar to multi-tissue regeneration. In addition, small explants of granulation tissue fragments from such actively treated wounds were found to produce undifferentiated cells in culture which underwent clonal expansion with no additional treatment [5]. These effects were traced to only the free silver ions introduced into the wound. All other biocompatible metallic ions were inactive and the electrical parameters were found to play no role in the process.

These observations raised the possibility that this dedifferentiation process in mammalian cells was the result of the action of the charged silver ion on some receptor site on the cell membrane. Therefore, it appeared possible that a similar effect could be produced without the requirement for the electrical parameters if a method for spontaneously releasing similar numbers of free silver ions from an appropriate substrate could be developed.

In conjunction with Omnishield, Inc. (PO Box 156, Elmhurst, PA 18447), an improved, patented process for producing a silver nylon material with unique properties has been developed. The process results in the controlled deposition of silver in a crystalline form rather than as a metallic deposit. The crystals are 50 nm in diameter, tabular, hexagonal and consist of pure silver. When moistened with any aqueous material including wound exudate, large numbers of free silver ions are released in a concentration controlled process dependent on the supply of receptor molecules. In *in vitro* tests, using distilled, deionized water, maximum silver release occurred in the first 3 minutes with equilibrium reached in 12 hours. Thereafter, equilibrium release was constant for over 48 hours. In similar tests using cell culture media (containing far more receptor molecules) the output of silver ions was 5 to 10 times greater.

It was theorized that the free silver ions spontaneously emitted by this fabric would have identical or similar effects on mature human cells as those emitted from positive silver electrodes. Both *in vitro* and clinical studies were designed to determine if dedifferentiation of normal mature human cells occurred and similar multi-tissue growth enhancement effects in refractory clinical wounds was produced. The advantage of the relatively simple technique of application of this silver fabric vs. iontophoretic application in wound treatment is evident. More importantly, if this simple technique results in the actual production of dedifferentiation in adult human cells, it may provide an alternative source of stem cells produced *in situ* where required, rather than employing embryonic stem cell transplants. In addition to avoiding the ethical problems associated with such transplants all possibility of donor-recipient incompatibility would be obviated.

2. Methods

2.1. *In vitro*

Two types of certified, normal, adult human cells were obtained from Clonetics Corporation, San Diego, CA: Normal Human Astrocytes, CC-2565, and Normal Human Dermal Fibroblasts, CC-2511. Stock cultures were grown in 80 cm² flasks in appropriate culture media. Log growth cultures were seeded to a density of 1×10^4 cells/well in 12-well culture plates (well diameter 2.5 cm) with each well containing a glass microscope cover slip and 2 ml of culture medium.

The culture plates were then incubated for 48 hours. They were then removed from the incubator, examined for cell density and substrate adhesion and the media was replaced. The cultures were then incubated for an additional hour at which time a 0.5 cm square disc of silver nylon or a similar sized piece of unsilvered nylon (to serve as a control) was inserted into the appropriate wells and incubated for periods of 1, 4, 8 and 12 hours under standard culture conditions. At the end of each time period the fabric discs were removed, the glass cover slips retrieved, fixed and stained (Wright's) for microscopic evaluation and photomicroscopy.

Photomicrographs were taken on Kodak TriX 35 mm film and processed in standard chemistry. No digital technology was employed. Prints were made to show a full frame image on 5 × 7 inch Ilford MG 4 print paper. Magnifications listed are optical, not photographic.

The criteria used for dedifferentiation were as follows;

- 1) Loss of normal external cytological anatomy and assumption of round cell type without distinguishing external characteristics.
- 2) Basophilic cytoplasm.
- 3) Increased basophilia of nucleus.
- 4) Increased nuclear-cytoplasmic ratio.
- 5) Loss of substrate adhesion with cells becoming free floating and tending to form clumps.

Arbitrarily, the appearance of 3 of the criteria were considered presumptive evidence for dedifferentiation.

2.2. *Clinical*

Nine patients have been treated thus far with silver nylon alone. All cases were patients with wounds that had been non-responsive to conventional therapy. Wounds were photographed with a Nikon 8008s camera with Kodak Gold 800 color negative film which was commercially processed and printed. For publication, prints were scanned and digitally printed in black and white without manipulation. Some wounds were cultured for bacterial flora and any necessary minor surgical debridement was done without anesthesia prior to beginning silver treatment.

Each patient was advised of the experimental nature of the treatment and possible side effects and was assured that they could terminate treatment at any time. Silver treatment was done in the patient's home except for Case #4 who was hospitalized for very serious unrelated conditions. Prior to beginning treatment, patients and/or caregivers were instructed in the proper appli-

cation of the silver nylon. In the majority of cases, the wound was initially dressed by the physician with explanation of each step to the patient. That demonstration dressing was removed and the patient, or caregiver was required to redress the wound in the physician's presence to ensure adequate treatment. In the four cases treated by other physicians, some of the above steps (wound photographs, removal of demonstration dressing) might have been omitted. Each patient was provided with an adequate amount of the silver nylon for one week treatment at home. The dressing procedure consisted of cutting an adequate size piece of silver nylon to cover, and pack the wound. This was thoroughly moistened with distilled water and applied so that contact between the silver nylon and all parts of the wound was obtained. The area was then covered with a moist cotton gauze dressing to provide gentle pressure and moisture. Initially, the dressing was left intact for 23 hours during which time the outer gauze dressing was sufficiently loosened (approximately every six to eight hours) to permit re-moistening of the silver nylon. At 23 hours, the dressing, including the silver nylon packing, was removed and discarded. The area was washed in tap water with approximately 10% by volume of hydrogen peroxide to provide mild chemical debridement. The wound was air dried for 20 minutes and a new dressing applied. Each patient was evaluated weekly. After the first week, treatment times were reduced to 8–10 hours daily with washing in water without peroxide at the end of each treatment followed by the application of a moist, sterile dressing which was permitted to dry until the next treatment. Two patients were treated by placement of several layers of silver nylon in the wound and covered by a moist cotton gauze dressing followed by a plaster cast. The cast was removed weekly (during which time the wound area was not examined) and the wound washed, similarly re-dressed and another cast applied until healing occurred.

3. Results: *In vitro*

3.1. *Normal human astrocytes*

Control cultures with plain nylon discs, grew quite slowly over the 12 hour period as individual cells in contact with the microscope cover glass. The cells were generally pleomorphic spindle or triangular in shape with long, primarily straight, narrow processes associated with the tips of the spindles. The nuclei were lightly basophilic and the cytoplasm was eosinophilic.



Fig. 1. Normal human astrocytes, exposed to silver nylon for 8 hours showing the boundary zone formed by the diffusion of the free silver ions from the silver nylon, 40X. The silver nylon square had been applied over the right quarter of the frame and unaffected astrocytes are visible in the left quarter of the frame.

In the experimental cultures with silvered nylon discs, beginning during the initial hour of exposure, the diffusion of free silver ions from the disc could be followed by changes in the cell morphology which produced a definite boundary zone between the area of the culture not yet exposed to the silver ions and the area in which the cells were exposed to the silver ions (see Fig. 1). In this latter area the cell bodies became round with highly basophilic nuclei with a thin rim of basophilic cytoplasm. Some level of substrate adhesion was maintained in the majority of the cells exposed to the silver ions. The long cell processes appeared to separate from the cell body and fragment into round cytoplasmic vesicles of variable size, sometimes appearing as a chain along the original path of the process.

3.2. *Normal human dermal fibroblasts*

In the control cultures, the cells grew well as a monolayer attached to the glass cover slip. Cytology was generally spindle shape with lightly basophilic nuclei and eosinophilic cytoplasm. There was a tendency for the cells to be arrayed in parallel rows producing occasional rounded or whorled structures.

In the experimental cultures a similar boundary zone could be observed expanding across the cover slip with time. All cells in the area exposed to silver ions lost substrate adhesion and became free floating occasionally forming clumps. They changed from the spindle morphology becoming round or ovoid. Cell size appeared reduced, but this could have been due to the rounding off process and loss of substrate adhesion.

Nuclei showed increased basophilia and the cytoplasm, which formed a thin rim about the nucleus, became basophilic.

In both cell types studied, the silver ions produced morphological changes compatible with the criteria for dedifferentiation beginning at approximately one hour of exposure.

4. Clinical results

Nine cases of chronic, infected wounds non responsive to standard therapy were treated with the application of silver nylon alone. Six of the cases were in insulin dependent diabetics with severe peripheral neuropathy and varying degrees of impaired peripheral circulation. Four of the diabetic cases were serious enough to have had amputations advised as a last resort or to have had prior amputations done for identical lesions on another extremity. One case was in a patient with severe peripheral neuropathy of unknown etiology. Two cases were traumatic wounds in otherwise normal patients. Both had also been advised amputation by the previous treating physician. In all cases infection control was achieved in 3 to 7 days and all treated wounds healed with restoration of all local tissues to their normal state. Times to full healing varied from three weeks to three months depending upon the extent of the initial condition. All diabetic cases with peripheral neuropathy demonstrated return of normal sensation, however only in the treated area and along the nerve tracts proximally and distally thereto. Sensory loss in adjacent areas not exposed to silver ions was not relieved. The return of sensation to the treated areas was generally complete but transitory, gradually diminishing until the area became asensate in about one year following treatment. Despite this subsequent sensory loss in the diabetic patients, all other regenerated tissues in the treated area remained normal for all follow up times.

In the two serious traumatic wounds (Patients #8 and 9) silver treatment was not begun until one month following the initial injury. Normal, fully innervated, full thickness epidermis was completely restored with dermatoglyphic lines and normal circulation. Sensory return was complete and, unlike the diabetic cases, has persisted to date. Circulatory return in all cases, diabetic and traumatic, was not strictly limited to the area of direct silver treatment, but occurred in the general area of the wound and its surroundings.

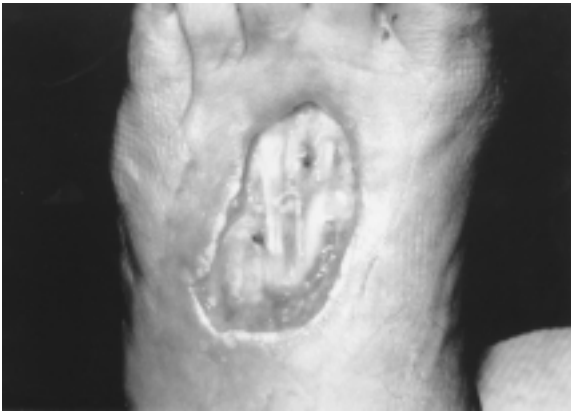

Fig. 2. Case #1, ulceration, left foot at start of silver treatment. The lateral border of the foot is to the left in the photograph and this same orientation is present in the remainder of the photographs of this case. The central area of the ulcer was covered by an adherent, yellow eschar imbedded in which are visible a number of extensor tendons. A narrow zone of apparently active tissue destruction is visible particularly in the proximal area.

The cases varied widely as to underlying condition and complicating circumstances and the results are not amenable to a simple tabular presentation. Case #1 is presented herewith in a complete clinical summary. The remaining cases are presented as clinical abstracts.

Case #1, A 75 year old, insulin dependent, retired dairy farmer with severe peripheral neuropathy noted the spontaneous appearance of a small (2 cm) blister on the dorsum of his left foot with no prior injury. This progressed to an aggressive ulcer which was diagnosed as epidermolysis gangrenosa and was initially treated with steroids, antibiotics and hyperbaric oxygen. A year prior to the present episode the patient had experienced a similar lesion on the dorsum of the right hand which rapidly progressed, ultimately requiring total amputation of metacarpals and digits 3, 4 and 5. This surgical incision had not completely healed when the present ulcer appeared on the left foot. The present ulcer continued to increase in size, mid foot amputation was advised and the patient sought silver treatment.

At the start of the silver nylon application the ulcer on the dorsum of the left foot measured 4.5×6.5 cm with a tough, yellow eschar firmly attached to the underlying tissues and involving the extensor tendons 2, 3 and 4. This ulcer was surrounded by a thin rim of actively necrotising tissue and erythema (see Fig. 2). A smaller ulcer (1×3 cm) was present in the center of the surgical incision on the right hand. This ulcer was quiescent without surrounding erythema. Sensation in both feet was absent from approximately the ankle distally with a similar, but less severe distribution in both hands. At

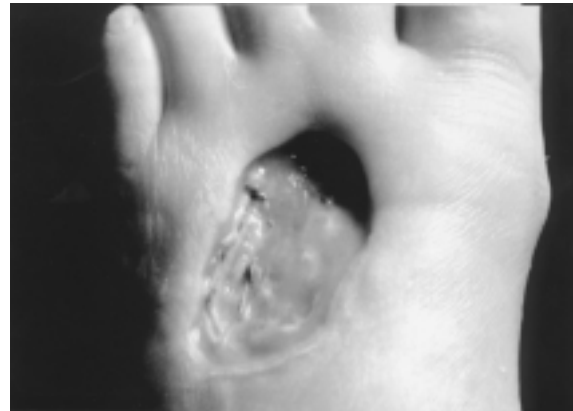


Fig. 3. Case #1, Ulceration, left foot, one month after start of silver treatment. The majority of the eschar has resolved, leaving a clean base with no evidence of remaining tendons. An early granulation is visible in the upper right area of the ulcer.

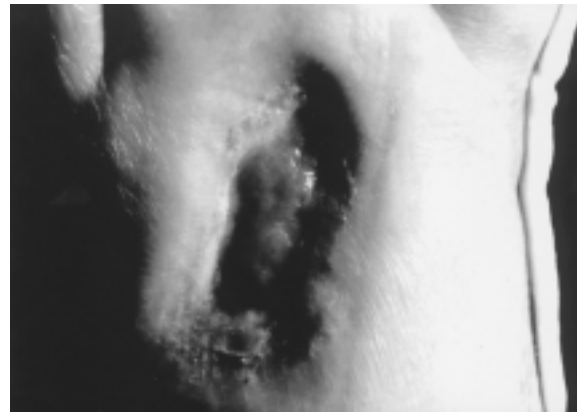

Fig. 4. Case #1, Ten weeks from start of the silver nylon treatment, the entire ulcer is now filled with active granulation tissue.

the beginning of silver treatment all antibiotics were discontinued. The steroid therapy was continued in order to be subsequently slowly withdrawn. Cultures from the left foot ulceration had been reported as negative, however slides made from the eschar revealed a population of unidentified gram positive cocci. Control of the blood sugar levels with insulin was extremely difficult. Silver nylon treatment of both lesions, right hand and left foot, was begun simultaneously.

Within one week, diabetic control was regained, advancement of the left foot ulcer was halted and healing of the incisional ulcer on the right hand had begun. At one month the right hand ulcer was completely healed and the eschar in the left foot ulcer had resolved leaving a clean base (see Fig. 3).

Six weeks after start of silver treatment the steroids were finally terminated and a few days later two similar




Fig. 5. Case #1, Status of original ulcer area on the left foot, 18 weeks after start of silver treatment. Normal skin has covered the entire area leaving only a small depression in the central area of the original ulcer.

blisters with surrounding erythema identical to those that preceded the epidermolysis lesions recurred on the residual dorsum of the right hand. One, approximately 1 cm in diameter the second about 2 cm. Both were treated by the application of moist silver nylon dressings within a few hours of their appearance. In 24 hours the blisters and erythema had resolved leaving a clean base with no erythema. These were treated with daily silver nylon dressings and both completely resolved with full skin healing in approximately 2 weeks. The steroid therapy was not restarted.

Granulation tissue growth began in the left foot ulcer at about the same time and progressed to an abundant growth filling the ulcer completely by approximately the 10th week after start of silver nylon therapy (Fig. 4). By approximately the 15th week after start of silver treatment skin healing of the left foot ulcer was complete (Fig. 5). Gradual return of sensation to the area of the ulcer and for about 1 to 2 cm proximal and distal thereto occurred starting about the 10th to the 12th week of treatment. By the 4th month after start of the silver treatment sensation was relatively complete on the dorsum of the foot over metatarsals 2, 3 and 4 and the corresponding toes. There was no return over the remainder of the foot and within approximately one year after the end of treatment the sensation in the left foot reverted to its pre treatment state. The patient was last seen two years and four months post treatment fully ambulatory, with no recurrence of ulcerations and continued good diabetic control.

Case 2, 64 year old male insulin dependent diabetic with pressure ulcer, right first metacarpal penetrating the joint space with spreading cellulitis of one month

duration, unresponsive to antibiotics. Amputation advised. A similar ulcer of the left foot one year prior required BK amputation. Present ulcer was 7×3 cm with 3 cm depth involving the metatarsal, cultures reported as pyocyanous and staph aureus. Sensation on entire foot and ankle absent and diabetic control was difficult. Antibiotics were terminated at start of silver treatment. One week later, cultures were negative, cellulitis resolved and insulin response normal. Three weeks later entire wound granulated in. Complete healing occurred in seven weeks with full thickness skin. Sensation restored to first metatarsal area, half of second metatarsal and entire toe. Follow up at one year, foot grossly normal, sensation diminished, patient fully ambulatory with left BK prosthesis.

Case 3, 52 year old male, insulin dependent diabetic with moderate to severe sensation loss both feet and ankles and pressure ulcer, lateral head 5th, right metatarsal, $2 \times 4.5 \times 1$ cm deep, with expanding cellulitis of 2 weeks duration. Two weeks after start of silver treatment cellulitis resolved, diabetic control restored and beginning granulation in ulcer. Complete healing with full thickness skin at 32 days. Sensation returned 4th and 5th toes and lateral side of foot to level of lateral malleolus by two months. Follow up at 16 months, foot grossly normal, diabetic control normal, sensation almost completely absent.

*Case 4**, 72 year old male insulin dependent diabetic with multiple problems, severe circulatory loss with cyanosis and ulceration of all finger tips, total sensation loss in both hands and feet, and renal and cardiac failure requiring peritoneal dialysis. Gangrene required surgical resection right first and second digits and metacarpals and left index finger. Both post operative wounds now grossly infected with expanding ulceration and cellulitis, loss of diabetic control, unresponsive to all antibiotics. Silver treatment to both sites was begun and one week later both infections were controlled, with no cellulitis and restoration of diabetic control. By six weeks left index finger amputation site fully healed, amputation site left metacarpal resections 75% healed, sensation returned to both sites and cyanosis resolved with restoration of circulation to treatment areas. Remainder of both hands still demonstrated sensation loss and cyanosis. Two weeks later patient suffered severe stroke, all treatments were stopped and patient sent to hospice care.

*Case 5**, 62 year old female insulin diabetic with impaired circulation and severe peripheral neuropathy of right foot resulting in Charcot type bone destruction in mid foot. A pressure ulcer developed over bone

protrusion, medial side of right mid foot which became infected and spread to multiple bones of midfoot. Amputation was recommended, patient elected surgical exploration which revealed multiple areas of bone destruction requiring radical debridement. Wound was left open and immediately packed with silver nylon which was left in place for 3 days. On removal wound was clean and silver nylon packing was thereafter administered on a 3 day schedule. After 3 weeks, wound was fully granulated in and full thickness skin closure was complete by the end of the ninth week. Significant circulatory improvement was noted over medial half of foot and nerve sensation returned to first toe and medial border of foot. On follow up at one year, circulation had remained improved but sensation was noticeably diminished.

*Case 6**, 64 year old female insulin dependent diabetic with a poorly placed, right mid foot amputation which resulted in shearing gait abnormality leading to a full thickness, infected ulcer, 3.5 cm diameter on the posterior sole. Antibiotic treatment failed to prevent expansion and silver treatment was begun with a composite dressing of silver nylon with thermoplastic backing material. The dressing was encased in a plaster cast which was left intact for one week. On removal, the wound was clean, without cellulitis and approximately 30% closed. Two more similar treatments were done and at the end of the third week the wound was completely healed with full thickness skin. The patient was provided with an adequate prosthesis and was able to ambulate normally. The treating surgeon indicated that the healing time was at least 50% of what had been expected. No information on sensory status was provided.

*Case 7**, 84 year old non diabetic female with peripheral neuropathy of unknown etiology, complete sensory loss over right foot and two ulcerations on sole, 2 cm and 1.5 cm in diameter. Both ulcers were expanding with local cellulitis non responsive to conservative treatment. Both ulcers were packed with silver nylon moist dressings and leg encased in plaster cast. Cast was removed at one week, both ulcers were clean and beginning healing. At the end of six weeks of similar treatment both ulcers were completely healed. The sensory defect remained unchanged.

Case 8, 36 year old male with crush injury to digits 3, 4 and 5 on left hand. Initial treatment was debridement, pin fixation of proximal phalanges. and multiple antibiotics. One month later, all involved digits had major areas of dry gangrene, 75% of digit 3, 50% of digit 4 and 40% of digit 5. Affected areas were black

with a tough, dense eschar firmly attached to underlying tissues. All involved fingers were fixed in claw position and amputations were advised. Initial silver treatment involved modest debridement of all eschars, application of iontophoretic silver to digit 3 and silver nylon dressings to 3 and 4. Dressings were continuous, changed daily and on day 7 the iontophoretic treatment was terminated. Treatment thereafter was continuous silver nylon dressings, changed daily and with daily debridement of eschar. At one month granulation healing had begun on digits 4 and 5. Small bone sequestae were being extruded from the terminal phalanx area of digit 3. Vigorous, assisted exercises were then begun for finger motion. By the end of the second month, full thickness skin healing of digits 4 and 5 was complete with return of full sensation and circulation. Healing of digit 3 was complete with full thickness, normally innervated skin by the end of the third month although the finger was 1.5 cm shorter due to loss of the terminal phalanx. Within one additional month, motion was approximately 90% of normal. On last follow up at 4 years status was the same and the patient was fully employed.

Case 9, 45 year old male, non diabetic with contaminated, traumatic amputations of the distal phalanx of the left great toe, the entire left 4th toe and distal phalanx of the left 5th toe. Initial treatment, debridement with wounds left open and multiple antibiotics. Overt infection of all wounds was evident by day 5 with cultures reported as *Enterococcus faecalis*, *Alcaligenes* and *Pseudomonas*. Antibiotics were adjusted but infections remained uncontrolled with spreading cellulitis proximally with tissue necrosis in the wounds and mid foot amputation advised but refused. Silver nylon treatment was begun 4 weeks post injury with termination of all antibiotics. Infection control was obtained within two days and healing with granulation begun by day 7. Healing, with full thickness skin with normal dermatoglyphic lines and full sensation and circulation was complete by 32 days. The only residual was 0.5 cm shortening of great toe with distorted nail. Follow up at two years revealed full ambulation and no symptoms.??

Note: * indicates case treated by other orthopedic surgeons with no supervision from author. Surgeons were supplied with adequate amounts of silver nylon and written instructions for use. In all instances the author did not see the patient and case summaries were derived from reports from the respective surgeons. Cases 5 and 7 were done by the same surgeon who is continuing to use silver nylon in his practice.

5. Discussion

Several aspects of the results of the silver ion treatment are of considerable clinical interest. There is an obvious superior local infection control in addition to an equally obvious increase in the healing rate and competency. Simultaneously, the treatment resulted in a noticeable local analgesic effect combined with an anti-inflammatory effect, both of which proved useful in therapy.

While the result of *in vitro* exposure of normal human cells to free silver ions is suggestive of a dedifferentiation process, obviously more work is required to firmly establish this.

The clinical healing demonstrated by the reported cases is further suggestive of a local tissue regenerative process. In this respect, the results of the use of silver nylon alone are quite comparable with the clinical results from the iontophoretic silver treatment [5]. Regardless of the mechanism(s) involved, the healing displayed by the treated wounds appears to be unique to the silver ion treatment. All treated wounds healed with full thickness, normally innervated skin and, in the cases with peripheral circulatory deficiency, restoration of normal local circulation. In most cases the final healed wound was visually normal with little or no evidence of the original ulcer or wound. The data reported here and in the preceding studies [4,5] indicates that the free silver ion is the primary causal agent. While some measure of dedifferentiation of mature human cells is clearly the primary effect, the possibility of stimulation of a population of pre-existing stem cells cannot be excluded. It should be noted that no undesirable clinical side effects of either method of silver ion treatment have been encountered at any time since the beginning of these studies in 1975. This may be compared with the mixed results reported from clinical studies involving transplantation of human, fetal stem cells [9].

The effect of the silver ion treatment on the nerves involved in the treatment area was particularly interesting. All patients reported a noticeable analgesic effect beginning in the first hour of treatment and persisting throughout the therapy. In all diabetic patients with pre-existing peripheral neuropathy relatively normal sensation was restored to the wound area and for a short distance proximal-distal thereto. While this effect was unfortunately transitory, sensory return in non diabetic, traumatic wounds has persisted for several years of follow up. These results suggest that the sensory loss in diabetics is due to a pathological lesion in the nerves that can be reversed by the silver treatment but

which recurs as the level of local silver deposition diminishes. It has been suggested that the primary lesion in diabetic peripheral neuropathy is in the Schwann cell sheath [17,12], a circumstance compatible with these observations. A variety of techniques are under consideration for introducing silver ions through intact skin in areas of diabetic peripheral neuropathy as a possible therapeutic measure.

6. Conclusions

It is concluded that local application of the type of silver nylon fabric used in this study is uniquely useful in the treatment of infected, non-healing wounds unresponsive to standard treatments. In addition to a major local antibiotic action a healing process closely resembling organized tissue regeneration is produced. The latter appears to be related to a dedifferentiation process induced in the mature cells of the treated wound tissues. While these *in vitro* and *in vivo* studies are preliminary, they appear to duplicate the previously reported results of iontophoretic silver treatment [4,5]. Both silver ion treatment methods have been shown to be safe and lacking significant side effects. Should these results be further substantiated, the range of treatment options for free silver ions may be expanded to include *in situ* treatment for clinical conditions for which fetal cell transplants are presently considered to be the only viable therapy.

Acknowledgement

The author acknowledges with appreciation the assistance of Philip Person, D.D.S., Ph.D. in the preparation of this manuscript.

References

- [1] Author, unpublished observations.
- [2] R.O. Becker, The bioelectric factors in amphibian limb regeneration, *J. Bone Joint Surg.* **43-A** (1961), 643–656.
- [3] R.O. Becker, Stimulating partial limb regeneration in rats, *Nature* **235** (1972), 109–111.
- [4] R.O. Becker, The effect of electrically generated silver ions on human cells, *Proceedings of the First International Conference on Gold and Silver in Medicine*, The Silver Institute, Bethesda, MD, 1987, pp. 227–243.
- [5] R.O. Becker, Effects of electrically generated silver ions on human cells and wound healing, *Electro- And Magnetobiology* **19** (2000), 1–19.

- [6] R.O. Becker and D.G. Murray, The electrical control system regulating fracture healing in amphibians, *Clin. Ortho. and Rel. Res.* **73** (1970), 169–198.
- [7] R.O. Becker and D.G. Murray, A method of producing cellular dedifferentiation by means of very small electrical currents, *Transactions New York Academy Science* **29** (1967), 600–615.
- [8] J.P. Brockes, Amphibian limb regeneration: rebuilding a complex structure, *Science* **276** (1997), 81–87.
- [9] C.R. Freed et al., Transplantation of embryonic dopamine neurons for severe Parkinson's Disease, *New Eng. J. Med.* **344** (2001), 710–719.
- [10] C. Illingworth, Trapped fingers and amputated finger tips in children, *Journal Pediatric Surgery* **9** (1974), 953–859.
- [11] C. Illingworth and A. Barker, Measurement of electrical current emerging during the regeneration of amputated finger and the tips in children, *Clinical Physical and Physiological Measurements* **1** (1980), 87–89.
- [12] S. Locke, Axons, Schwann cells and diabetic neuropathy, *Bulletin New York Academy of Medicine* **45** (1967), 784–789.
- [13] D.H. Lowenstein and S.M. Parent, Brain heal thyself, *Science* **283** (1999), 1126–1127.
- [14] E. Marshall, The business of stem cells, *Science* **287** (2000), 1419–1421.
- [15] S. Smith, Induction of partial limb regeneration in Rana pipiens by galvanic stimulation, *Anatomical Record* **158** (1967), 89–97.
- [16] D. Stocum, New tissues from old, *Science* **276** (1997), 15.
- [17] P. Thomas and R. Lascelles, Schwann cell abnormalities in diabetic neuropathy, *Lancet* (1965), 1355–1357.
- [18] P. Weiss, Perspectives in the field of morphogenesis, *Quarterly Review Biology* **25** (1950), 172–198.
- [19] F.E. Young, A time for restraint, *Science* **287** (2000), 1424.